

TOSHIBA

Leading Innovation >>>

Medical **R**evie**w**

Approaches to the Diagnosis of Liver Fibrosis

Hiroko Iijima

Department of Hepatobiliary
and Pancreatic Disease,
Ultrasound Imaging Center,
Hyogo College of Medicine



Approaches to the Diagnosis of Liver Fibrosis

Hiroko Iijima

Department of Hepatobiliary and Pancreatic Disease, Ultrasound Imaging Center, Hyogo College of Medicine

Dr. Hiroko Iijima graduated from Hyogo College of Medicine in 1983 and joined the Third Department of Internal Medicine of Hyogo College of Medicine as a clinical fellow in the same year. She was appointed assistant in the Third Department of Internal Medicine of Hyogo College of Medicine in 1996 and lecturer in the Fourth Department of Internal Medicine of Tokyo Medical University in 2000. In 2003, Dr. Iijima was appointed clinical professor in the Department of Radiology at Toronto General Hospital of the University of Toronto and visiting professor in the Department of Medical Biophysics at the Sunnybrook Research Institute of the University of Toronto. She was appointed associate professor in the Medical Imaging Center and associate professor in the Division of Hepatobiliary and Pancreatic Disease of the Department of Internal Medicine of Hyogo College of Medicine in 2005. Since 2008, Dr. Iijima has served as the director of the Ultrasound Imaging Center and a professor in the Department of Hepatobiliary and Pancreatic Disease.



Introduction

The conventional methods employed in diagnostic ultrasound examinations for chronic liver diseases include the assessment of B-mode images, the evaluation of nonuniformity in the Rayleigh distribution (ASQ), and the estimation of disease progression based on indices of congestion as well as hepatic vein waveforms obtained by Doppler scanning. Following the introduction of ultrasound contrast agents, estimation of the severity of liver diseases based on the times required for contrast agent to reach the hepatic arteries, portal vein, and hepatic veins and functional diagnosis based on the phagocytic activity of Kupffer cells have also been performed.

In this paper, I would like to discuss the assessment of liver stiffness using shear waves, which is one of the recently developed elastography methods that is attracting a great deal of interest.

Background of the development of elastography

When conventional methods based on the observation of speckle patterns in B-mode images are used for the diagnosis of liver diseases, the diagnosis of F2 and F1 stages is very difficult. There have been attempts to perform tissue diagnosis using images of the liver surface, but these are morphologic methods and provide no more information than the estimation of liver stiffness by manual palpation.

Toshiba Medical Systems Corporation has implemented a method known as Acoustic Structure Quantification (ASQ) for the assessment of nonuniformity within

the liver in their diagnostic ultrasound system Aplio™. However, this function only analyzes the uniformity of the liver parenchyma.

Currently, the gold standard for the diagnosis of liver diseases is considered to be liver biopsy. However, liver biopsy suffers from a number of problems and limitations, including the risk of complications, invasiveness, high cost, and the possibility of sampling error. Blood chemistry examinations are also employed, but their diagnostic accuracy is not particularly high.

Clinically, it is important to determine the risk of cancer and the need for antiviral treatment in each individual patient. For patients with hepatitis C, it is also necessary to determine whether treatment can be postponed until direct-acting antiviral (DAA) agents become available on the market. Assessment of the degree of fibrosis and inflammation is important for these clinical applications.

Given this background, elastography, which can be used to assess hepatic fibrosis and stiffness noninvasively, has been developed and is increasingly employed in the clinical setting.

Two main trends in elastography

There are two types of elastography: strain elastography, which assesses the degree of strain when a given amount of force is applied to the liver, and shear wave elastography, which assesses the velocity of shear wave propagation within the liver.

If shear waves are explained using an earthquake as an example, the longitudinally vibrating P waves propagate more quickly and the transversely vibrating S waves propagate more slowly. In the human body as well, the transversely vibrating shear waves propagate slowly, at a velocity of 1 m/s to 10 m/s. In addition, the propagation velocity differs significantly depending on the tissue stiffness. These characteristics make it possible to detect shear waves using a diagnostic ultrasound system. The pressure that is needed to induce 100% strain in the target tissue is represented by the modulus of elasticity (kPa), and the velocity of shear wave propagation that is obtained by "poking" one point and then observing the vibration at another point is referred to as

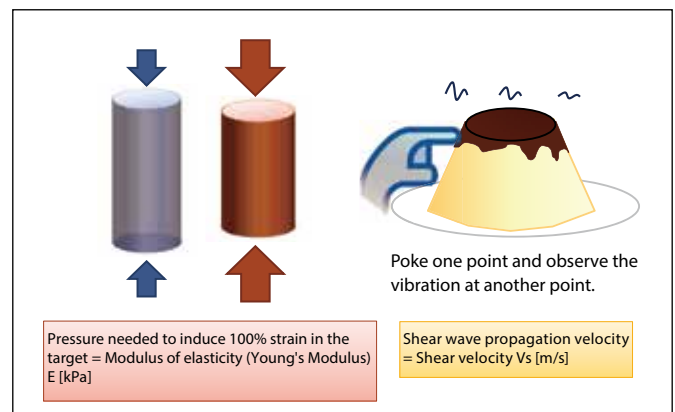


Figure 1. Relationship between shear velocity and tissue stiffness.

the "shear velocity" (Fig. 1).


In the new Shear Wave Elastography (SWE) method that has been developed by Toshiba, a part of the tissue is deformed by a "push pulse", the velocity of the shear waves propagating within the tissue is detected, and the stiffness of the tissue is assessed based on the detected shear velocity (Fig. 2a). If an obstacle such as a tumor is present in the tissue, the shear velocity in that area differs from the shear velocity in the surrounding areas. If the

obstacle is stiffer than the surrounding tissues, the shear waves propagate faster (Fig. 2b), and if the obstacle is softer, the shear waves propagate slower. The propagating shear waves are detected by transmitting search pulses.

When the time at which the shear waves have reached each distance is plotted with the horizontal axis representing the propagation distance and the vertical axis representing time, a tracing showing the propagation of shear waves within the

liver is obtained (Fig. 3). In uniform tissue, the shear velocity does not change and the tracing is a straight line. But if the shear velocity changes, the slope of the tracing also changes. For example, if a stiff tumor is present in the liver, the area in which the shear velocity is higher (i.e., the area that is determined to be stiffer) is displayed in red on the screen.

One of the major features of SWE is that it is possible to select "continuous scan", in which the frame rate can be



a: A part of the tissue is deformed by a push pulse.
b: The shear velocity is higher in a stiff obstacle such as a tumor.

Figure 2. Changes in shear velocity in SWE.

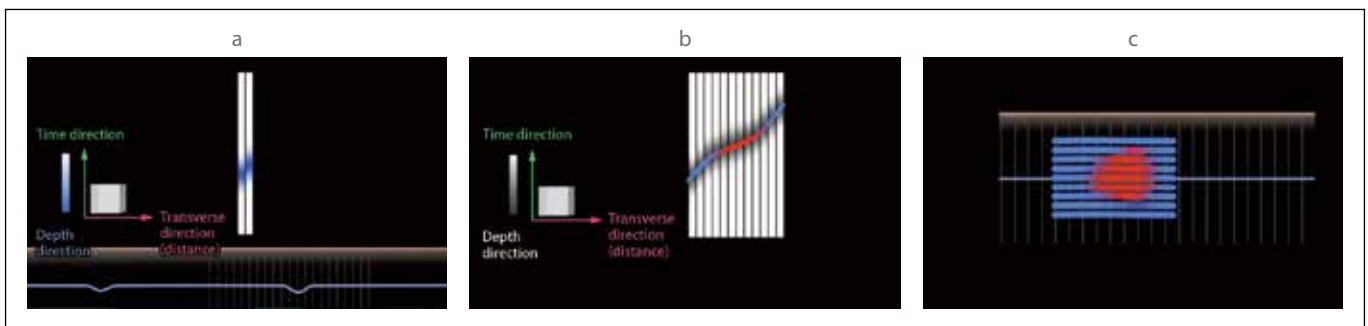


Figure 3. Tracing of shear waves in SWE. The depth direction represents time. A tracing of shear wave propagation is shown. The blue lines indicate that the shear wave has passed.

• Switching among three display modes is possible after freezing.

- Shear velocity : Speed mode [m/s]
- Modulus of elasticity : Elasticity mode [kPa]
- Arrival time contour : Propagation mode

speed [m/s]

elasticity [kPa]

propagation

Figure 4. Features of SWE.

Switching among three display modes is possible after freezing.

Display in Propagation mode

- Background and purpose
 - To determine **whether the shear waves propagate properly.** To measure the stiffness in areas where the shear waves propagate properly.
 - Propagation display shows **whether the shear waves are generated and propagate as expected in a single still image.**

Stiff target

Soft target

Figure 5. Arrival time contours in SWE.

Display in Propagation mode

selected in three steps, or "one-shot scan", in which image quality is given higher priority. Continuous scan is advantageous for evaluating areas that are likely to be affected by cardiac motion, but at our institution, we select one-shot scan in order to obtain higher image quality. Another major feature of SWE is that images can be viewed using three different display modes after freezing: Speed (shear velocity) mode (m/s), Elasticity mode (kPa), and Propagation (arrival time contour) mode (Fig. 4).

Usefulness of shear wave arrival time contours

In conventional elastography methods, there is no means for determining whether or not the shear waves propagate properly based on the displayed color images. With SWE, it is possible to observe whether the shear waves propagate properly through the tissue in a single still image displayed in Propagation (arrival time contour) mode (Fig. 5).

The intervals between the displayed

contour lines are wider in stiff tissues and narrower in soft tissues. In diffuse diseases with no obstacles, the shear velocity does not change and the intervals between the contour lines should be constant. In areas where the contour lines are parallel, the shear waves propagate properly and the reliability of the obtained data is high. In areas where the contour lines are distorted and not parallel to one another, the reliability of the obtained data is low. In other words, the reliability of the data can be verified by observing the contour lines (Fig. 6).

SWE is designed so that no color is displayed in areas where data reliability is low due to the influence of blood vessels in Speed mode as well, but shear wave propagation can be observed more clearly in contour display. In addition, contour display makes it possible to verify the data reliability in deeper regions where shear waves are difficult to generate.

As discussed above, arrival time contour display is very useful for verifying the

reliability of the data and for selecting suitable areas for shear velocity measurement. For example, even in a patient with severe fatty liver and a skinfold thickness of 3 cm, it was possible to obtain data with verified reliability by determining the area in which the shear waves propagate uniformly using contour display and measuring the shear velocity within this area (Fig. 7).

Clinical data for SWE

Clinical data obtained at our institution in the period from January 31 to April 3, 2014, is shown. The targets were 236 cases in which liver stiffness was measured using two or more ultrasound system models and 64 cases in which liver biopsy was performed.

Case 1 was diagnosed as F1 and A1 (chronic hepatitis) based on the liver biopsy findings. It can be confirmed that in the areas displayed in clear blue in Speed mode, the shear waves propagate uniformly in Propagation mode (Fig. 8).

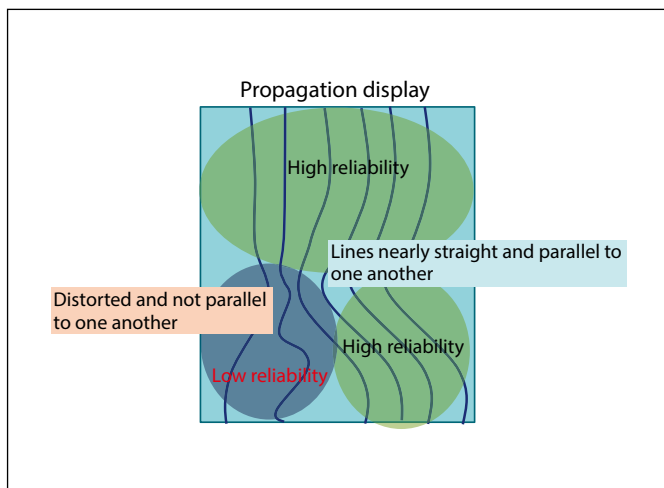


Figure 6. Reliability of propagation display based on the contour lines.

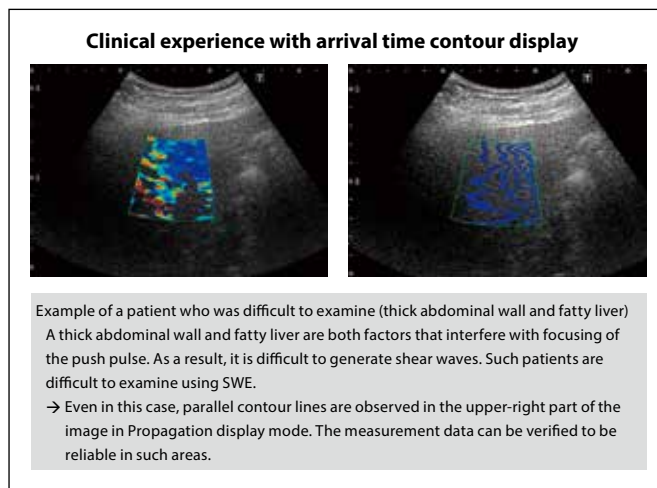


Figure 7. Verifying data reliability based on arrival time contour display.

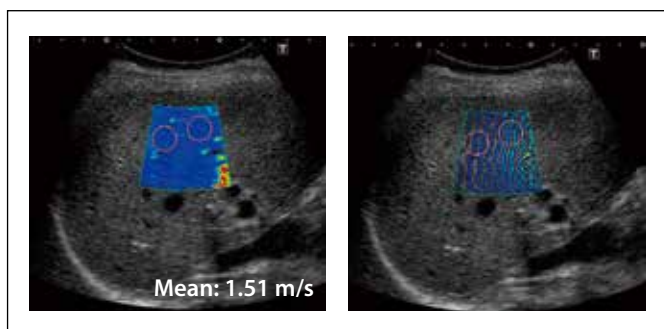


Figure 8. Case 1: F1, A1 (chronic hepatitis).

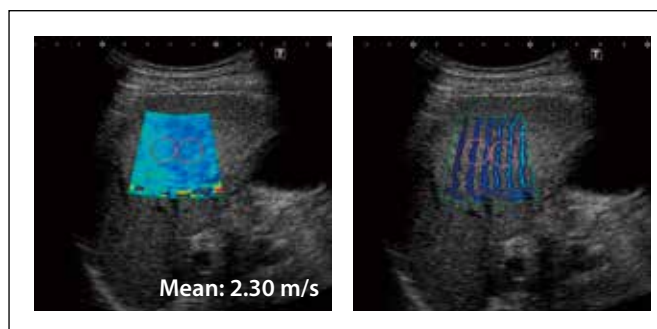


Figure 9. Case 2: F3, A1.

The blood vessels are displayed in black.

Case 2 was diagnosed as F3 and A1 based on the liver biopsy findings. The color tone of the image is more yellowish than in case 1 (Fig. 9). The intervals between the contour lines are slightly wider, and the shear velocity measurement is 2.3 m/s.

Case 3 was diagnosed as liver cirrhosis (F4). The image appears significantly more yellowish than in case 2 (Fig. 10). Red areas are also observed, clearly indicating stiff tissues. The intervals between the contour lines are even wider than in case 2. The platelet count was $7.8 \times 10^4 \mu\text{L}^{-1}$ and the serum albumin level was 3.5 g/dL. The shear velocity measurement is 3.32 m/s.

At our institution, we use diagnostic ultrasound systems manufactured by three different companies in addition to the Toshiba Aplio. The correlation coefficients between the measurement values obtained using Aplio and those obtained using the systems from each of the other companies were 0.884, 0.852, and 0.938, suggesting that the reliability of the measurement values obtained using SWE developed by Toshiba is comparable to that of conventional products.

In the 64 cases in which liver biopsy was performed, the correlation coefficients for the Aplio compared with the systems from each of other companies were obtained. The results were 0.927, 0.916, and 0.959,

indicating statistically significant high correlations.

When the relationships between the liver biopsy findings and shear velocity values obtained using Aplio were analyzed, the box plots showed that the diagnostic capabilities for F4 were high, although there were several extreme outliers (Fig. 11). The mean shear velocity was 1.646 m/s in cases diagnosed as F1, 1.762 m/s in cases diagnosed as F2, 2.213 m/s in cases diagnosed as F3, and 2.862 m/s in cases diagnosed as F4, indicating that the measurement values increased in parallel with the degree of fibrosis.

With regard to the cases in which significant mismatch was observed

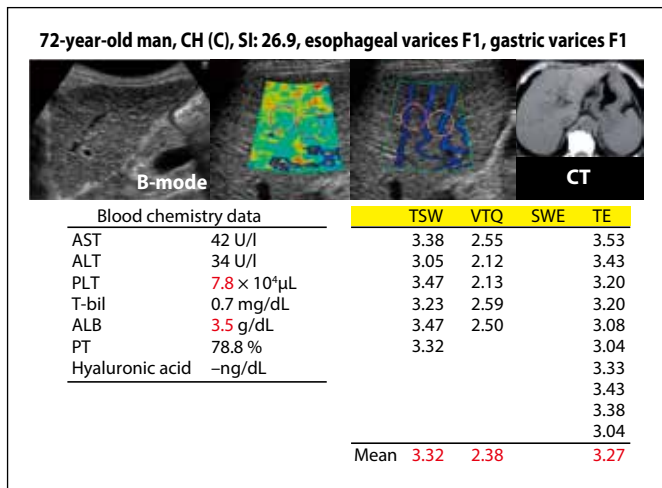


Figure 10. Case 3: F4 (liver cirrhosis)

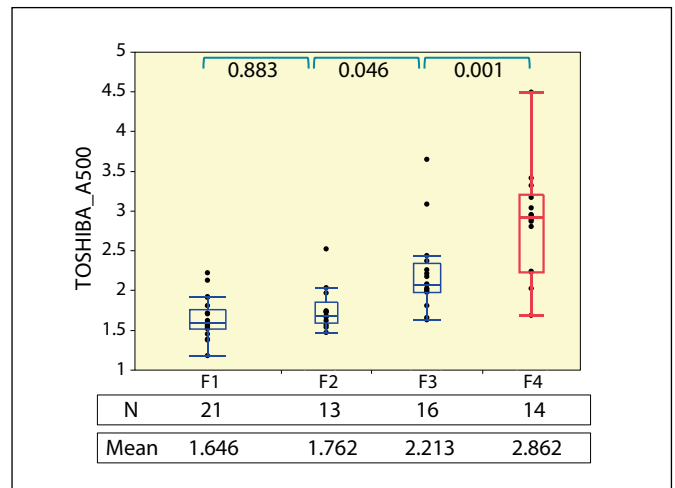


Figure 11. Comparison with liver biopsy findings.

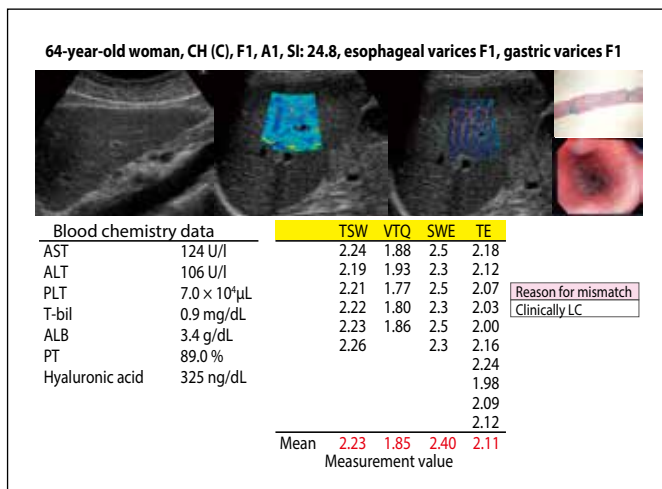


Figure 12. Case 4: F1, clinically diagnosed as liver cirrhosis.

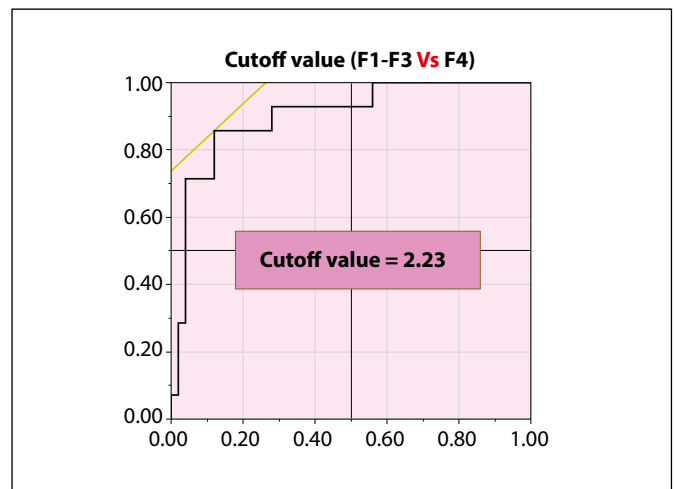


Figure 13. Cutoff value for the diagnosis of liver cirrhosis using SWE.

(2.23 m/s)

F1-F3 Vs F4 = 'F4' is assumed to be positive.

Area under the ROC curve = 0.90143

between the liver biopsy findings and the measurement values, these cases had, for example, been diagnosed as F1 based on the liver biopsy findings but clinically found to have liver cirrhosis complicated by gastric and esophageal varices (Fig. 12). In case 4, high measurement values were obtained by systems other than Aplio. The tissue specimens obtained by liver biopsy contained wide areas of fibrosis, but this case was diagnosed as F1 by the pathologist. Since the image displayed in Speed mode of SWE is yellowish and the intervals between the contour lines are wide, it appears possible to diagnose this case as liver cirrhosis.

Based on the results obtained at our

institution, the cutoff value for cirrhosis in SWE was calculated to be 2.23 m/s, although the number of cases was small (Fig. 13). Cases in which the shear velocity is 2.23 m/s or higher can be diagnosed as having liver cirrhosis. The area under the ROC curve was 0.9, which is excellent.

Conclusion

The liver stiffness measurement function of the new elastography method known as SWE developed by Toshiba Medical Systems Corporation was found to have diagnostic capabilities for fibrosis comparable to the analogous functions of systems manufactured by other companies. It was confirmed that the

shear velocity measured by SWE tends to increase in parallel with the degree of fibrosis.

Arrival time contour display, which is a major feature of SWE, makes it possible to observe whether the shear waves propagate properly, allowing the reliability of the obtained data to be verified. With systems other than Aplio, when images are displayed with mottled colors in elastography images, the reliability of the data may be questionable and it is often necessary to repeat the examination several times. With Aplio, it is expected that reliable data can be obtained in a single examination by observing the shear wave arrival time contours.



TOSHIBA MEDICAL SYSTEMS CORPORATION

<http://www.toshibamedicalsystems.com>

©Toshiba Medical Systems Corporation 2014. All rights reserved.
Design and specifications subject to change without notice.
Model number:TUS-A500 MOIUS0074EA 2014-09 TME/D

Toshiba Medical Systems Corporation meets internationally recognized standards for Quality Management System ISO 9001, ISO 13485.

Toshiba Medical Systems Corporation Nasu Operations meets the Environmental Management System standard ISO 14001.

Made for Life and Aplio are trademarks of Toshiba Medical Systems Corporation.

Printed in Japan