

Advances in 3D Speckle Tracking: Activation Imaging

John Gorcsan III, MD

University of Pittsburgh, Division of Cardiology, Pittsburgh, USA

Activation Imaging is an exciting new 3D mechanical activation mapping tool using echocardiography. Activation Imaging was developed because of a particular interest in the electrophysiology community to localize the onset of electroanatomical activation non-invasively with ultrasound.

Activation Imaging

During cardiac electrical activation, the impulse travels down the heart, from the septum to the apex, and then back up to the ventricular walls with a very predictable activation sequence. Before Activation Imaging, electroanatomical mapping could only be done using catheter-based systems, such as the CARTO system. Activation Imaging is the first non-invasive 3D mechanical activation mapping tool. Potential clinical applications

include LV lead placement for cardiac resynchronization therapy (CRT), mechanical activation for ablation and evaluation of the effects of cardiac pacing.

When the heart is not functioning properly, different segments activate at different moments in time. Activation Imaging, in conjunction with Toshiba's comprehensive 3D Wall Motion Tracking software, allows clinicians to evaluate dyssynchrony at the onset of the heart's contraction and to properly identify the left ventricle's pumping strength and timing.

Activation Imaging utilizes color coding to track the mechanical activation of the heart, focusing on the early part of the cardiac cycle. After

normalizing all the 3D strain waveforms, a specified threshold is set and defined as the start of mechanical activation. Each segment is then identified and color coded according to the time it takes for it to cross this threshold. Clinicians have the ability to set the color coding, starting with red or blue, for additional customization.

Activation Imaging provides a 3D color overlay of the mechanical activation and is defined using strain values. The activated regions are detected frame by frame. In the figure below, regions activated in the first frame are colored red. Areas activated in subsequent frames are colored orange, yellow and green. This sequence of Activation Imaging in the 3D display shows clinicians the entire range of activation (Figure 1).

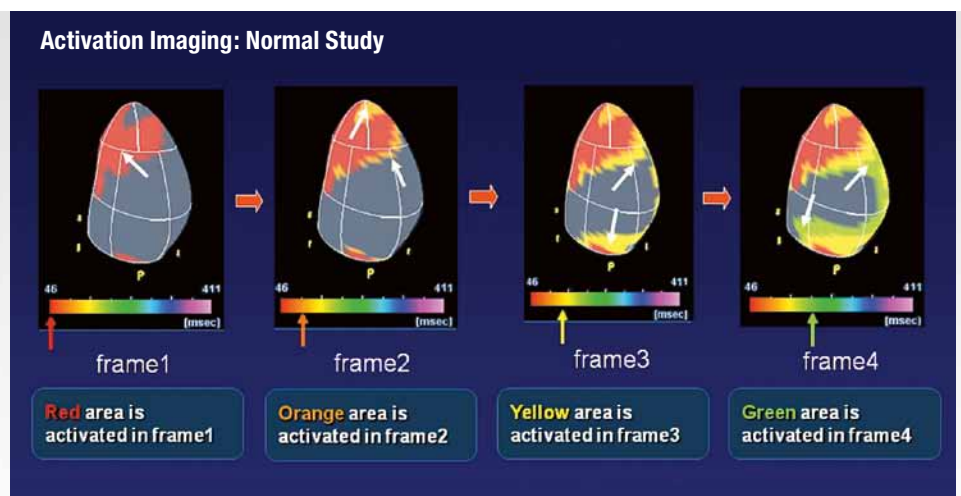


Figure 1: Activation Imaging – Frame by frame color coding.

2 Advances in 3D Speckle Tracking: Activation Imaging

In a normal patient, the activation starts in the apex (denoted by red) and then moves along with sequential colors. The activation mechanically starts in the apex, moving rapidly up the ventricular walls, similar to squeezing a tube of toothpaste from the bottom (Figure 2).

In patients with abnormal electrical activation, this new technology holds great promise for clinicians to diagnose issues more accurately and non-invasively. In this example, the patient has a left bundle branch block as indicated by the large area of green in the lateral LV wall (Figure 3). Activation Imaging can be shown in both 3D

plastic-bag orientation and a polar map to quantify the activation times. The timing is shown in milliseconds for this normal subject (Figure 4).

The orientation of the images can be manipulated for different views. In this example, the activation images are in an apex-up orientation. A normal patient is being compared to one with left bundle branch block, with late-activating regions shown in orange and red in the posterior LV wall. These images clearly demonstrate the left bundle branch block in the patient on the right (Figure 5). The polar maps of these same patients show quantitative measurements of the activation. The normal

patient activates early and uniformly, starting at the apex. The patient with left bundle branch block has very late segments in the posterior region. The activation of 229 milliseconds is later than the 92 milliseconds in the normal subject. Also, the activation in the anteroseptal region is earlier than normal (Figure 6).

Evaluating the Effects of CRT

One of the most interesting potential clinical applications of Activation Imaging is tracking changes before versus after CRT. In the patient with left bundle branch block, the site of latest activation is clearly defined (Figure 7). Following electrical

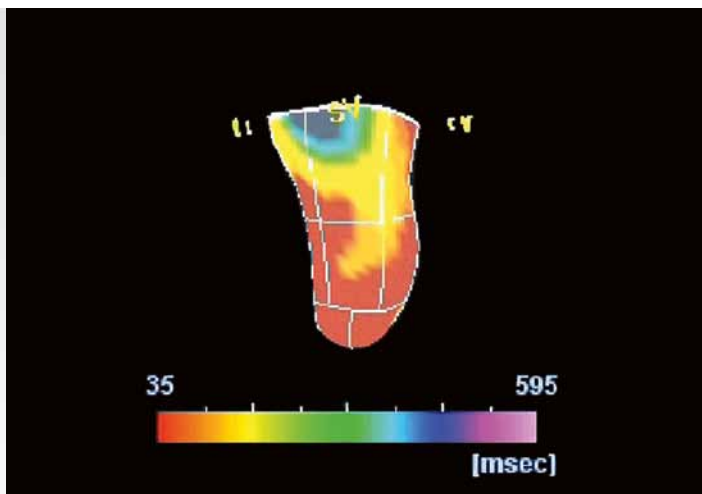


Figure 2: Activation Imaging showing normal study.

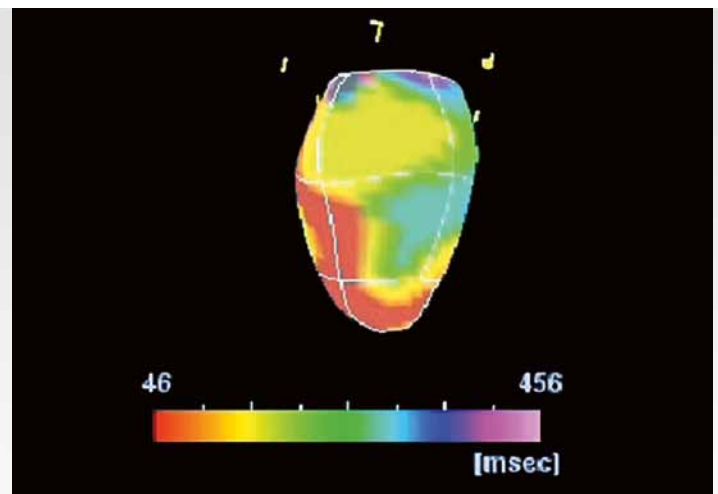


Figure 3: Cardiac study showing Left Bundle Branch Block (LBBB).

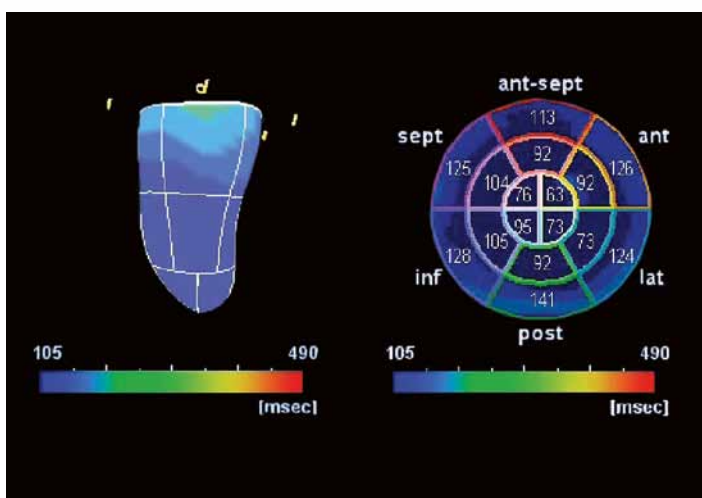


Figure 4: Activation Imaging can be shown in plastic bag and/or polar map view.

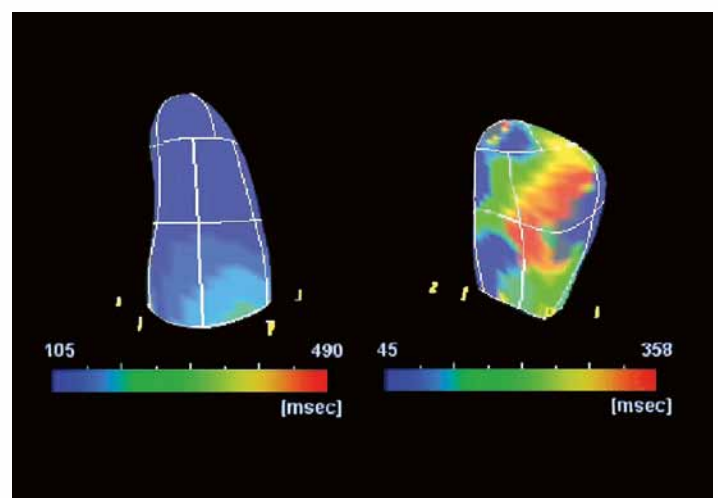


Figure 5: Normal study (left) and LBBB (right).

lead placements and proper pacing, there is re-synchronization, or re-coordination, of the activation of the mechanical sequence. The polar maps also demonstrate more uniform activation, and provide quantification of the physiology of activation (Figure 8).

Research Applications

Activation Imaging was recently used in a study to determine the differences in RV pacing for heart failure patients with left bundle branch block versus native conduction. After performing RV pacing on patients with left bundle branch block, a shift of the earliest activation point from the

base to the mid-septum was visualized, resulting in increased dyssynchrony and a decreased ejection fraction. Among patients with a low ejection fraction, it became even lower with dyssynchrony. This was uniquely shown with Activation Imaging. These and other latest advances and clinical applications were recently presented at a special symposium during the 2013 American Society of Echocardiography National Scientific Sessions (Figure 9).

Conclusion

Activation Imaging is an exciting new technology that holds great promise in quantifying the effects of cardiac pacing and the mechanical activation for ablation in tachyarrhythmias.

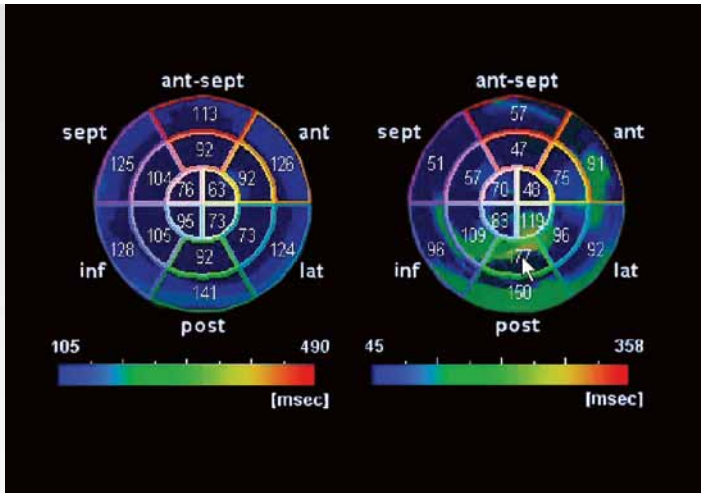


Figure 6: Polar maps of normal study (left) and LBBB (right).

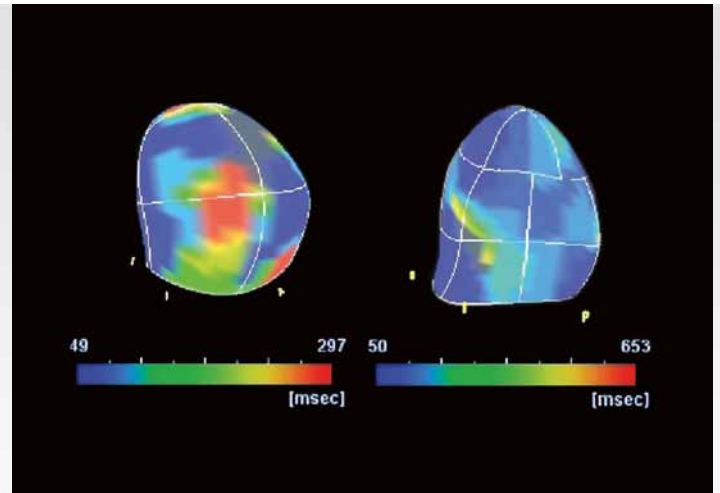


Figure 7: Before (left) and after (right) CRT.

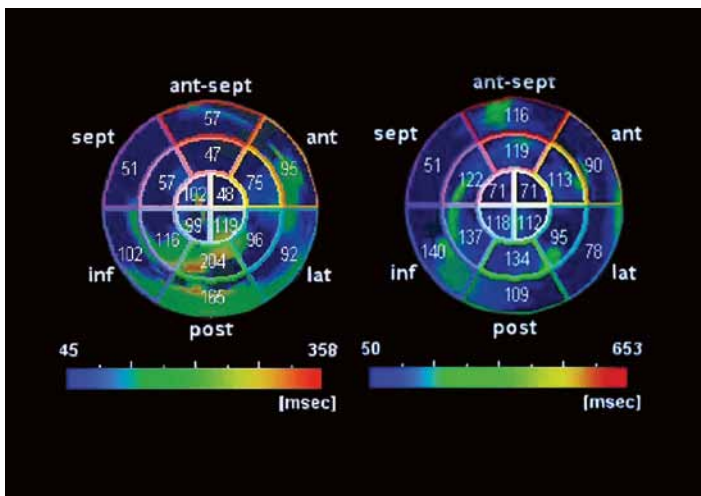


Figure 8: Polar maps of before (left) and after (right) CRT.

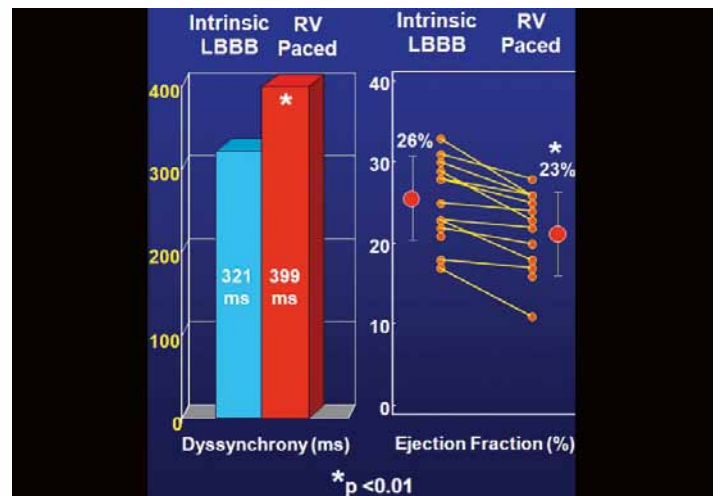


Figure 9: Activation Imaging showing increased dyssynchrony and decreased ejection fraction in patients with LBBB after RV pacing.

TOSHIBA MEDICAL SYSTEMS CORPORATION

©Toshiba Medical Systems Corporation 2013 all rights reserved.
Design and specifications subject to change without notice.
11/2013 MWPUL0024EUC
Printed in Europe

www.toshiba-medical.eu



ULTRASOUND CT MRI X-RAY SERVICES